

Detection of glaucoma progression by perimetry and optic disc photography at different stages of the disease: results from the Early Manifest Glaucoma Trial

HannaMaria Öhnell,¹ Anders Heijl,² Harald Anderson³ and Boel Bengtsson²

¹Department of ophthalmology, Lund University, Skane University Hospital, Malmö, Sweden

²Department of Clinical Sciences in Malmö, Ophthalmology, Faculty of Medicine, Lund University, Malmö, Sweden

³Department of Clinical Sciences Lund, Cancer Epidemiology, Faculty of Medicine, Lund University, Lund, Sweden

ABSTRACT.

Purpose: To compare the earliest detection of progression in visual fields and monoscopic optic disc photographs at different stages of manifest glaucoma.

Methods: This study evaluated 306 eyes in 249 patients with manifest open-angle glaucoma included in the Early Manifest Glaucoma Trial (EMGT). All patients in the trial were followed up regularly by standard automated perimetry and monoscopic optic disc photography, and the median follow-up time was 8 years. Progression was assessed in series of optic disc photographs and in series of visual fields using glaucoma change probability maps and the predefined EMGT progression criterion. The proportion of progressions detected first in visual fields and the proportion detected first in optic disc photographs were compared at different stages of glaucoma severity defined by the perimetric mean deviation (MD) of the baseline visual field.

Results: Assessment of 210 eyes with early visual field loss, 83 eyes with moderate field loss, and 13 eyes with advanced field loss showed that, among the eyes exhibiting progression, the progression was detected first in the visual field in 80%, 79% and 100%, respectively. The predominance of visual field progressions at all stages was still apparent when using narrower (3-dB) MD intervals for staging.

Conclusion: In the EMGT material on eyes with manifest open-angle glaucoma, the initial progression was detected much more often in the visual field series than in the optic disc photographs at all stages of disease.

Key words: EMGT – glaucoma stage – open-angle glaucoma – optic disc – progression – visual field

Acta Ophthalmol. 2017; 95: 281–287

© 2016 The Authors. Acta Ophthalmologica published by John Wiley & Sons Ltd on behalf of Acta Ophthalmologica Scandinavica Foundation and European Association for Vision & Eye Research.

This is an open access article under the terms of the Creative Commons Attribution-NonCommercial-NoDerivs License, which permits use and distribution in any medium, provided the original work is properly cited, the use is non-commercial and no modifications or adaptations are made.

doi: 10.1111/aos.13290

Introduction

It is currently widely assumed that structural progression precedes functional

progression in glaucomatous eyes. However, available evidence is conflicting, indicating that structural progression occurs first in one subset of

patients, and functional progression first in other subsets, and there is often surprisingly weak agreement between the two modalities in longitudinal studies (Miglior et al. 1996; Kerrigan-Baumrind et al. 2000; Artes & Chauhan 2005; Anderson 2006; Hood & Kardon 2007; Gonzalez-Hernandez et al. 2009; Harwerth et al. 2010; Leung et al. 2011; Leite et al. 2012; Malik et al. 2012; De Moraes et al. 2013; Banegas et al. 2015; Raza & Hood 2015). The guidelines of the World Glaucoma Association and the European Glaucoma Society advocate regular monitoring of both structural and functional changes, particularly in patients with early glaucoma damage (Medeiros et al. 2011; The European Glaucoma Society 2014). Nonetheless, when resources are limited, the question arises as to whether follow-up using both structural and functional methods are necessary at all stages of the disease. To the best of our knowledge, no longitudinal clinical studies have compared the value of following structural and functional progression at different stages of manifest glaucoma.

The Early Manifest Glaucoma Trial (EMGT) evaluated the effectiveness of reducing intraocular pressure (IOP) in previously untreated open-angle glaucoma (Leske et al. 1999). The EMGT results represent an unusual longitudinal material comprising regular and long-term prospective follow-up of both the visual field and the optic disc.

Accordingly, the EMGT data are well suited for studying structural and functional progression at different stages of the disease spectrum. The aim of this study was to compare the earliest detection of glaucoma progression in series of visual fields and optic disc photographs at different stages of the disease.

Patients and Methods

Patients were recruited to the EMGT (National Institutes of Health ClinicalTrials.gov identifier NCT00000132. Date of registration: September 23, 1999) primarily through a large population-based screening based on optic disc appearance and IOP performed between 1992 and 1997 (Leske et al. 1999). In all, 255 patients aged 50–79 years were included and randomized 1:1 to treatment with argon laser trabeculoplasty plus betaxolol 5 mg/ml B.I.D. (Betoptic[®], Alcon, Fort Worth, TX, USA), or to no treatment. Having at least one eye with a reproducible glaucomatous visual field defect as determined by the glaucoma hemifield test (GHT) of the Humphrey perimeter (Carl Zeiss Meditec, Dublin, CA, USA) was required for eligibility, thus subjects could have one or both eyes included in the study. Patients with one or more of the following were not eligible: advanced visual field loss with mean deviation (MD) worse than -16 dB or threat to fixation; mean of all prestudy measurements of IOP >30 mmHg; any IOP measurement >35 mmHg in at least one eye. The patients that were included underwent follow-up every 3 months for the first 4 years. Visual fields were examined at each visit, whereas optic disc photography was performed every 6 months; with one additional photograph 3 months after baseline. After 4 years, a minority of patients were shifted to follow-up visits every 6 months, if deemed suitable by the treating ophthalmologist.

The present investigation was conducted according to the tenets of the Declaration of Helsinki and the patients provided informed consent. The study was approved by the Ethics Committee of the University of Lund (Sweden) and the Committee on Research Involving Human Subjects of the State University of New York at Stony Brook (USA).

Visual field progression was determined according to predetermined criteria. Tentative field progression was defined as three or more of the same test locations in glaucoma change probability maps showing statistically significant progression compared to baseline in two consecutive visual fields (Bengtsson et al. 1997; Leske et al. 1999). If tentative progression occurred, the patient was scheduled for an additional visit 1 month later to confirm visual field progression in the same test locations. The date of the third of these visual fields was defined as the date of the visual field progression. The glaucoma change probability maps were based on the pattern deviation to eliminate effects caused by media opacities or cataracts. In our analyses, visual field progressions meeting these criteria were not considered to represent true glaucoma progression, if either of the following applied: the findings could be explained by other conditions or the same three or more test locations did not indicate sustained change in subsequent visual fields.

In the EMGT, fundus photography was performed through a dilated pupil using a modified 30° Zeiss fundus camera and Kodachrome 64 film until the technique was changed in 2005, and thus, up to 11 years of follow-up photographs were obtained with the same instrument. The photographs were digitized for this study. Baseline images were defined as photographs from the 3-month visit, rather than those acquired at the prerandomization baseline visit, to avoid any possible changes in optic disc configuration caused by introducing pressure-lowering treatment (Tan & Hitchings 2004; Prata et al. 2011). Fundus photographs obtained after 2005 were not used in our analysis, as this would have prevented masking of the temporal order of images.

The three disc readers (BB, AH, HMÖ) independently evaluated each optic disc to identify progression. The disc reading procedure is described in detail elsewhere (Öhnell et al. 2016). Briefly, the readers were masked to the temporal order of the photographs and all other patient data. Pairs of photographs from the 3-month visit and the last available photographs were presented in random chronological order and were mixed with control

pairs comprising two different photographs obtained at the same visit. Any progression that was detected in the pair analysis had to be sustained throughout the rest of the series when the three disc readers subsequently judged the whole series of the same eye unmasked for temporal order. The date when progression was first observed defined the date of optic disc progression. Complete sequences of fundus photographs for all eyes were also analysed by one of the readers (HMÖ) to rule out that any additional progressions could be detected in this manner. Disagreement between the readers was settled through consensus.

The disc reading was performed in a dimly lit room using high-quality computer screens that could magnify photographs to the desired size. Progression was determined as changes in the course of vessels on the optic disc surface or visible changes in the disc rim configuration (e.g. evident increased notching). Changes in pallor or peripapillary atrophy were not considered as evidence of progression nor were the occurrence of optic disc haemorrhages. Our group (Öhnell et al. 2016) has published a random sample of a dozen optic discs deemed to have progressed to illustrate the magnitude of changes required to classify a disc as progressing.

The glaucoma stage at baseline was determined by visual field status. Primarily, we used the perimetric MD intervals presented in the Hodapp–Parrish–Anderson Glaucoma Grading Scale (GGS) (Hodapp et al. 1993). The studied eyes were categorized as having *early field loss* ($MD \geq -6$ dB), *moderate field loss* (-12 dB \leq MD < -6 dB) or *advanced field loss* (-20 dB \leq MD < -12 dB). In reality, the group with advanced field loss only included eyes with MD values down to -16 dB, which was the lower limit for eligibility in the EMGT. In as much as this acknowledged GGS is rather crude, with wide intervals for MD, and also considering that the EMGT mainly included eyes with early-to-moderate field loss, we performed a subanalysis using finer grading of MD in 3-dB intervals.

Statistical analysis

Inter-rater agreement among the disc readers was calculated using the

Table 1. Type of progression detected first depending on glaucoma stage.

	Visual field progression first <i>n</i> (%)	Optic disc progression first <i>n</i> (%)	Simultaneous progression <i>n</i> (%)	No progression <i>n</i> (%)	Total
MD ≥ -6 dB	109 (52)	27 (13)	1 (0)	73 (35)	210
-12 dB ≤ MD < -6 dB	46 (55)	12 (14)	0 (0)	25 (30)	83
-16 dB ≤ MD < -12 dB	8 (62)	0 (0)	0 (0)	5 (38)	13
Total	163 (53)	39 (13)	1 (0)	103 (34)	306

arithmetic mean of Cohen’s kappa values and prevalence- and bias-adjusted kappa (PABAK) values. (Light 1971; Byrt et al. 1993; Hallgren 2012). The percentage distribution between structural and functional progression was determined in each of the subgroups according to the Hodapp–Parrish–Anderson GGS and the narrower MD-groups in 3-dB intervals. Cumulative incidence functions (Marubini & Valsecchi 2004) were computed for the different GGS stages. Competing events were optic disc progression first, visual field progression first and death occurring within 6 months from the last follow-up visit. In the early and moderate glaucoma groups, confidence intervals for the various cumulative incidences at 96 months (median follow-up time) were determined using a bootstrap technique with 1000 repetitions and patient as cluster, as some patients provided both eyes as study eyes (Efron & Tibshirani 1986). For eyes in which progression had occurred, we also calculated the conditional probability that optic disc progression or visual field progression occurred first. In the early and moderate glaucoma groups, robust 95% confidence intervals were determined using patient as cluster variable (Williams 2000). In the advanced glaucoma group, all patients contributed one eye each, and hence, standard confidence intervals were used for both cumulative incidences and conditional probabilities. Statistical analyses were performed using the Statistical Package for the Social Sciences (IBM Corp. released 2013. IBM statistics for Macintosh, version 22.0. Armonk, NY: IBM Corp.) and STATA (StataCorp. 2015. STATA: Release 14. Statistical software. College Station, TX: StataCorp LP.)

at baseline, and 66% were female. In our study, nine eligible eyes in six patients had to be excluded because the follow-up was too short to allow detection of any progression (i.e. fewer than two fundus photographs or three visual fields were available after baseline). Thus, 306 eyes in 249 patients remained for our analyses, and both eyes were investigated in 57 of the patients. The median follow-up time was 96 months (8 years), with a minimum of 9 months and a maximum of 132 months.

At baseline, glaucoma was early in 210 eyes, moderate in 83 eyes and advanced in 13 eyes according to the GGS. The median MD values for the three groups were -2.96 dB, -7.96 dB and -13.44 dB, respectively. Corresponding mean IOP values at 3 months were 17, 17 and 18 mmHg.

In our assessments, three of the studied eyes that fulfilled the EMGT visual field progression criterion were classified as having no glaucomatous

field progression: one of those eyes developed haemianopia during follow-up, and the progression initially identified in the other two eyes was not sustained during the rest of the visual field series. The inter-rater reliability for the three disc readers gave an arithmetic mean of Cohen’s kappa of 0.500, and the arithmetic mean of the PABAK was 0.634, representing substantial agreement. None of the control pairs were erroneously rated as ‘progression’ by the disc readers. In 222 eyes, all three disc readers agreed on the existence of progression or not after individual classifications. Consensus was reached for the remaining 84 eyes.

Visual field progression was detected first about four times more often than optic disc progression in both the group with early and the group with moderate defects (Table 1 and Fig. 1). All progressions were detected first in the visual field in the group with advanced defects, but this group included considerably fewer eyes than

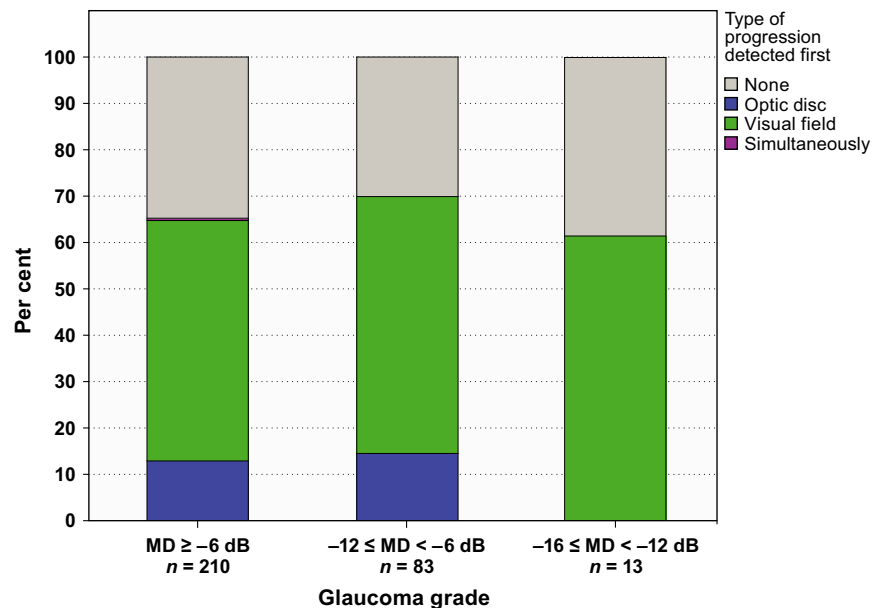


Fig. 1. Percentage distribution of visual field progression and optic disc progression occurring first in the different Glaucoma Grading Scale groups. Visual field progression occurred first much more frequently than optic disc progression in all groups.

Results

The 255 patients included in the EMGT had a median age of 68 years

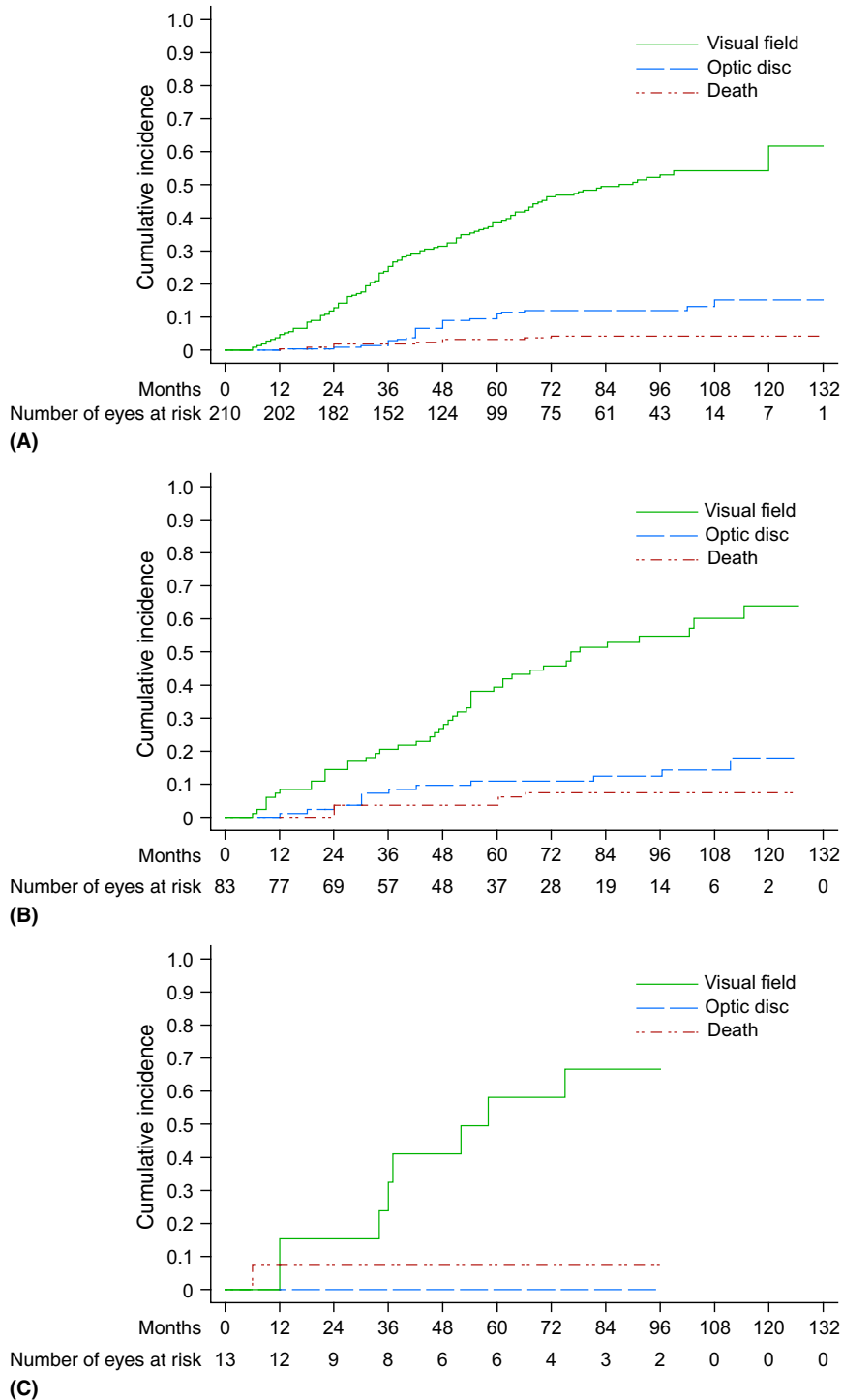


Fig. 2. Cumulative incidence functions for eyes with early (A), moderate (B) and advanced (C) field loss at inclusion in the Early Manifest Glaucoma Trial. The graphs show cumulative incidences for the competing events; visual field progression first, optic disc progression first and death first occurring within 6 months from the last follow-up visit.

the other two groups. The conditional probability that the first type of progression would be detected in the visual field, given that any type of progression occurred, was 80% [robust 95% confidence interval (CI) 72%–86%] in the early damage group, 79% (robust 95%

CI: 67%–88%) in the moderate group and 100% (one-sided 97.5% CI: 63%–100%) in the advanced group. After 96 months of follow-up, the cumulative incidence of visual field progression occurring first was found to be 53% (95% CI: 46%–60%), 55%

(95% CI: 43%–67%) and 67% (95% CI: 34%–86%) for the three groups, respectively (Fig. 2A–C). During the same month, the corresponding values for optic disc progression occurring first were 12% (95% CI: 8%–17%), 14% (95% CI: 7%–22%) and 0%.

Repeating the same calculations using the narrower 3-dB MD intervals yielded a similar proportion of progressions detected by structural and functional methods in the four groups where MD values ranged from normal to –12 dB, with markedly more extensive detection of visual field progression before optic disc progression. Likewise, none of the eyes in the group with MD worse than –12 dB showed optic disc progression first (Fig. 3).

Discussion

Visual field progression prior to optic disc progression appeared to have occurred considerably more often than optic disc progression prior to visual field progression, and this was noted at all stages of glaucoma, and possibly even more frequently in advanced glaucoma. Though, the number of eyes with advanced glaucoma in the EMGT was few. Nevertheless, we could not confirm the assumption that structural progression precedes functional progression in glaucomatous eyes.

The present results on optic disc progressions differ from those published in the first EMGT report 227 (Heijl et al. 2002), which were obtained at an optic disc reading centre by flicker chronoscopy of disc photographs. During the EMGT, it became clear that visual fields had a greater impact on the outcome of evaluations, and hence, the Data Safety and Monitoring Committee closed the EMGT’s optic disc reading centre in 2002. In the current investigation, we reanalysed all series of digitized monoscopic fundus photographs in a masked fashion and strived to achieve high sensitivity. We also used a longer follow-up time and detected considerably more optic disc progressions than in our earlier report (Heijl et al. 2002).

A strength of the present study is that it used material from the EMGT, which was a randomized, prospective, screening-based trial that had long follow-up time and hence provided unique regular documentation of both the visual fields and the optic discs.

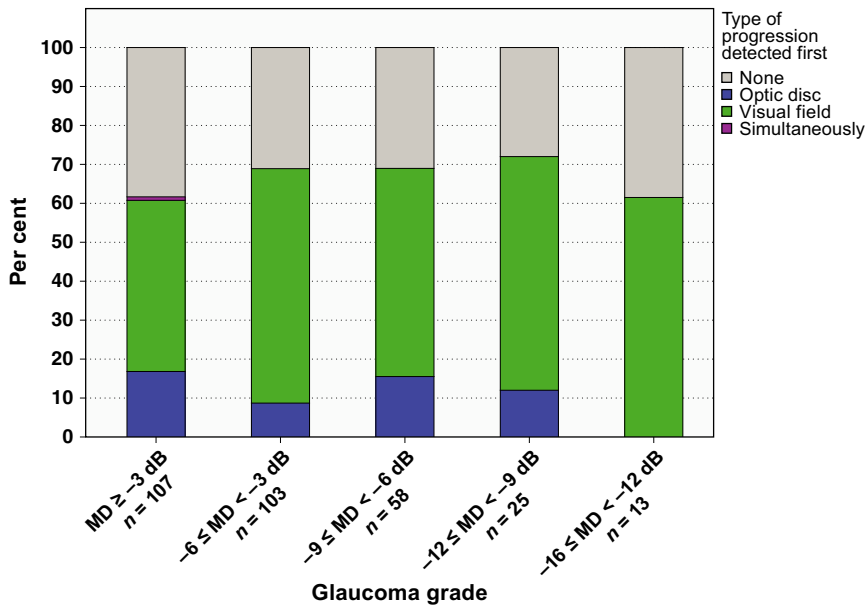


Fig. 3. Percentage distribution of visual field progression and optic disc progression occurring first in eyes categorized according to MD at baseline in 3-dB intervals. The relationship between structural and functional progressions was similar in all groups. In the first group (MD values better than -3 dB), 17% of eyes showed optic disc progression first and 44% showed visual field progression first. Corresponding rates for the other four groups were as follows: 9% versus 60%, 16% versus 53%, 12% versus 60% and 0% versus 62%.

Fundus photographs were collected every 6 months and visual fields every 3 months. As we had such long follow-up, it was possible to maintain also high specificity, by requesting that progression detected in any of the modalities could be confirmed to persist during the follow-up, except if progression was noted at the very end of follow-up. Non-sustained progression was not considered true glaucoma progression. The visual field criterion in EMGT has earlier been demonstrated to show a high specificity (Heijl et al. 2008; Artes et al. 2014), and also in the present study, only three patients were found to be false positives during follow-up and not considered true progression. That none of the control discs were erroneously marked as 'progression' is also a measure of specificity.

We used the EMGT criteria for visual field progression, where the date of progression is set at the third of the visual fields determining progression, mostly 4 months after the first of the three visual fields. In contrast, the first optic disc photograph where we could detect optic disc progression was used as the date of progression. This would even out the disparity in time intervals for the different modalities, and for simultaneous progressions; it would represent a slight advantage for

detection of progression in the optic disc. Treatment was generally initiated or changed after the first progression was detected, and therefore, any possible subsequent progression in the other modality could theoretically be delayed. Consequently, only the first type of progression detected was taken into consideration in our analyses.

A weakness of our study is that we used monoscopic fundus photographs, while stereoscopic fundus photographs are often regarded as the preferred method for assessing the status of the optic disc. However, monoscopic fundus photographs were used in EMGT, and they are also commonly employed in clinical practice, although in that context they are seldom subjected to such rigorous analysis as in the present study. Earlier reports have not found any substantial difference in the ability of monoscopic versus stereoscopic photographs to determine the diagnosis of glaucoma (Varma et al. 1992; Chan et al. 2014), but longitudinal comparisons in detecting progression is lacking. It would have been interesting to compare visual field progression with that identified by modern imaging techniques using built-in interpretation tools. However, such methods were not available when the EMGT was initiated, and results thus far have been

conflicting regarding the ability of those techniques to predict visual field loss (Chauhan et al. 2001, 2009; Mohammadi et al. 2004; Artes & Chauhan 2005; Strouthidis et al. 2006; Heeg & Jansonius 2009; Weinreb et al. 2010; Leung et al. 2011; Medeiros et al. 2014; Schrems-Hoesl et al. 2014).

To the best of our knowledge, this is the first longitudinal clinical report to describe the structure–function relationship in different stages of manifest glaucoma. Only a few studies have assessed the structure–function relationship longitudinally in patients with manifest glaucoma and the results have been inconsistent. For example, (Chauhan et al. 2001, 2009) showed that structural progression occurred first more often, whereas Miglior et al. (1996) found substantially more functional progression in eyes with glaucoma. De Moraes et al. (2013) reported slightly more visual field progressions among their glaucoma cases retrospectively.

The findings of different investigations regarding the detection of structural and functional progressions depend on the methods used to detect structural and functional changes, as well as the stage of glaucomatous disease in the study population and the follow-up time. The effect of choice of method used to detect progression is demonstrated by the fact that even for different structural methods, the correlation is rather poor (O'Leary et al. 2010; Banegas et al. 2015). The studies conducted by Kerrigan-Baumrind et al. (2000) and Harwerth et al. 1999; Harwerth et al. (2002) are frequently cited as supporting the assertion that structural progression precedes functional progression. Notwithstanding, as has previously been pointed out by other authors, (Hood & Kardon 2007; Malik et al. 2012) the mentioned investigations do not fully support this claim, because there is very large variability in the visual field loss noted at different levels of measured loss of retinal ganglion cells. In contrast, Raza & Hood (2015) concluded that statistically significant retinal ganglion cell loss did not occur more often than statistically significant visual field loss among preperimetric and early glaucoma cases. The curvilinear relationship that has been suggested (Harwerth et al. 1999; Leite et al. 2012; Medeiros et al. 2012; Alasil et al. 2014) is likely a

result of the logarithmic scaling of the visual field, as described by Garway-Heath et al. (2000, 2002); Garway-Heath (2004) and Leite et al. (2012). The studies advocating a curvilinear relationship have compared logarithmic visual field loss of the entire field or sectors of the field with different measures of structural deterioration. Instead, we used glaucoma change probability maps in which certain points show significant deterioration, often in the vicinity of earlier field loss. This ability to detect progression in previously less affected points in the visual field is not as dependent on the degree of earlier damage in other areas of the visual field (Heijl et al. 1989), which might explain why functional progression was detected essentially equal often throughout different stages of manifest glaucoma in our study. Still, comparing with our earlier published results showing an equal ability to detect progression with monoscopic optic disc photographs and automated perimetry in eyes with preperimetric glaucoma (Öhnel et al. 2016), it is somewhat surprising that we could not detect a higher proportion of optic disc progressions during earlier stages of manifest glaucoma, with a gradual increase of perimetric progression through more advanced stages of the disease.

In conclusion, our evaluation of series of visual fields and optic disc photographs of eyes in the EMGT with early-to-moderate field loss showed that progression occurred first in the visual field more often than in the optic disc, regardless of the stage of the disease.

References

Alasil T, Wang K, Yu F et al. (2014): Correlation of retinal nerve fiber layer thickness and visual fields in glaucoma: a broken stick model. *Am J Ophthalmol* **157**: 953–959.

Anderson RS (2006): The psychophysics of glaucoma: improving the structure/function relationship. *Prog Retin Eye Res* **25**: 79–97.

Artes PH & Chauhan BC (2005): Longitudinal changes in the visual field and optic disc in glaucoma. *Prog Retin Eye Res* **24**: 333–354.

Artes PH, O’Leary N, Nicoleta MT, Chauhan BC & Crabb DP (2014): Visual field progression in glaucoma. What is the specificity of the Guided Progression Analysis. *Ophthalmology* **121**: 2023–2027.

Banegas SA, Anton A, Morilla-Grasa A, Bogado M, Ayala EM & Moreno-Montanes J (2015):

Agreement among spectral-domain optical coherence tomography, standard automated perimetry, and stereophotography in the detection of glaucoma progression. *Invest Ophthalmol Vis Sci* **56**: 1253–1260.

Bengtsson B, Lindgren A, Heijl A, Lindgren G, Asman P & Patella M (1997): Perimetric probability maps to separate change caused by glaucoma from that caused by cataract. *Acta Ophthalmol Scand* **75**: 184–188.

Byrt T, Bishop J & Carlin JB (1993): Bias, prevalence and kappa. *J Clin Epidemiol* **46**: 423–429.

Chan HH, Ong DN, Kong YX, O’Neill EC, Pandav SS, Coote MA & Crowston JG (2014): Glaucomatous optic neuropathy evaluation (GONE) project: the effect of monoscopic versus stereoscopic viewing conditions on optic nerve evaluation. *Am J Ophthalmol* **157**: 936–944.

Chauhan BC, McCormick TA, Nicoleta MT & LeBlanc RP (2001): Optic disc and visual field changes in a prospective longitudinal study of patients with glaucoma: comparison of scanning laser tomography with conventional perimetry and optic disc photography. *Arch Ophthalmol* **119**: 1492–1499.

Chauhan BC, Nicoleta MT & Artes PH (2009): Incidence and rates of visual field progression after longitudinally measured optic disc change in glaucoma. *Ophthalmology* **116**: 2110–2118.

De Moraes CG, Liebmann JM, Park SC, Teng CC, Nemiroff J, Tello C & Ritch R (2013): Optic disc progression and rates of visual field change in treated glaucoma. *Acta Ophthalmol Scand* **91**: e86–e91.

Efron B & Tibshirani RJ (1986): Bootstrap methods for standard errors, confidence intervals, and other measures of statistical accuracy. *Stat Sci* **1**: 54–77.

Garway-Heath DF (2004). Comparison of structural and functional methods -I. In: Weinreb RN & Greve EL (ed.). *Glaucoma diagnosis. Structure and function*. The Hague, Kugler publications 135–143.

Garway-Heath DF, Caprioli J, Fitzke FW & Hitchings RA (2000): Scaling the hill of vision: the physiological relationship between light sensitivity and ganglion cell numbers. *Invest Ophthalmol Vis Sci* **41**: 1774–1782.

Garway-Heath DF, Holder GE, Fitzke FW & Hitchings RA (2002): Relationship between electrophysiological, psychophysical, and anatomical measurements in glaucoma. *Invest Ophthalmol Vis Sci* **43**: 2213–2220.

Gonzalez-Hernandez M, Pablo LE, Armas-Dominguez K, de la Vega RR, Ferreras A & de la Rosa MG (2009): Structure-function relationship depends on glaucoma severity. *Br J Ophthalmol* **93**: 1195–1199.

Hallgren KA (2012): Computing inter-rater reliability for observational data: an overview and tutorial. *Tutor Quant Methods Psychol* **8**: 23–34.

Harwerth RS, Carter-Dawson L, Shen F, Smith EL 3rd & Crawford ML (1999): Ganglion cell losses underlying visual field

defects from experimental glaucoma. *Invest Ophthalmol Vis Sci* **40**: 2242–2250.

Harwerth RS, Crawford ML, Frishman LJ, Viswanathan S, Smith EL 3rd & Carter-Dawson L (2002): Visual field defects and neural losses from experimental glaucoma. *Prog Retin Eye Res* **21**: 91–125.

Harwerth RS, Wheat JL, Fredette MJ & Anderson DR (2010): Linking structure and function in glaucoma. *Prog Retin Eye Res* **29**: 249–271.

Heeg GP & Jansonius NM (2009): The groningen longitudinal glaucoma study III. The predictive value of frequency-doubling perimetry and GDx nerve fibre analyser test results for the development of glaucomatous visual field loss. *Eye* **23**: 1647–1652.

Heijl A, Lindgren A & Lindgren G (1989): Test-retest variability in glaucomatous visual fields. *Am J Ophthalmol* **108**: 130–135.

Heijl A, Leske MC, Bengtsson B, Hyman L & Hussein M (2002): Reduction of intraocular pressure and glaucoma progression: results from the Early Manifest Glaucoma Trial. *Arch Ophthalmol* **120**: 1268–1279.

Heijl A, Bengtsson B, Chauhan BC, Lieberman MF, Cunliffe I, Hyman L & Leske MC (2008): A comparison of visual field progression criteria of 3 major glaucoma trials in Early Manifest Glaucoma Trial patients. *Ophthalmology* **115**: 1557–1565.

Hodapp E, Parrish RK & Anderson DR (1993): *Clinical decisions in glaucoma*. St Louis: Mosby.

Hood DC & Kardon RH (2007): A framework for comparing structural and functional measures of glaucomatous damage. *Prog Retin Eye Res* **26**: 688–710.

Kerrigan-Baumrind LA, Quigley HA, Pease ME, Kerrigan DF & Mitchell RS (2000): Number of ganglion cells in glaucoma eyes compared with threshold visual field tests in the same persons. *Invest Ophthalmol Vis Sci* **41**: 741–748.

Leite MT, Zangwill LM, Weinreb RN, Rao HL, Alencar LM & Medeiros FA (2012): Structure-function relationships using the Cirrus spectral domain optical coherence tomograph and standard automated perimetry. *J Glaucoma* **21**: 49–54.

Leske MC, Heijl A, Hyman L & Bengtsson B (1999): Early manifest glaucoma trial: design and baseline data. *Ophthalmology* **106**: 2144–2153.

Leung CK, Liu S, Weinreb RN et al. (2011): Evaluation of retinal nerve fiber layer progression in glaucoma: a prospective analysis with neuroretinal rim and visual field progression. *Ophthalmology* **118**: 1551–1557.

Light RJ (1971): Measures of response agreement for qualitative data: some generalizations and alternatives. *Psychol Bull* **76**: 365–377.

Malik R, Swanson WH & Garway-Heath DF (2012): ‘Structure-function relationship’ in glaucoma: past thinking and current concepts. *Clin Exp Ophthalmol* **40**: 369–380.

- Marubini E & Valsecchi MG (2004): Analysing survival data from clinical trials and observational studies. Chichester: John Wiley & sons Ltd 335–344.
- Medeiros FA, deMoraes G, Chauhan BC, Susanna R & Liebmann JM (2011): Structure and function. In: Weinreb RN, Garway-Heath DF, Leung C, Crowston JG & Medeiros FA (eds.). Progression of glaucoma. Consensus series- 8. World Glaucoma Association. Amsterdam: Kugler publications 91–99.
- Medeiros FA, Zangwill LM, Bowd C, Mansouri K & Weinreb RN (2012): The structure and function relationship in glaucoma: implications for detection of progression and measurement of rates of change. *Invest Ophthalmol Vis Sci* **53**: 6939–6946.
- Medeiros FA, Lisboa R, Zangwill LM, Liebmann JM, Girkin CA, Bowd C & Weinreb RN (2014): Evaluation of progressive neuroretinal rim loss as a surrogate end point for development of visual field loss in glaucoma. *Ophthalmology* **121**: 100–109.
- Miglior S, Brigatti L, Lonati C, Rossetti L, Pierrotet C & Orzalesi N (1996): Correlation between the progression of optic disc and visual field changes in glaucoma. *Curr Eye Res* **15**: 145–149.
- Mohammadi K, Bowd C, Weinreb RN, Medeiros FA, Sample PA & Zangwill LM (2004): Retinal nerve fiber layer thickness measurements with scanning laser polarimetry predict glaucomatous visual field loss. *Am J Ophthalmol* **138**: 592–601.
- Öhnell HM, Heijl A, Brenner L, Anderson H & Bengtsson B (2016): Structural and functional progression in the Early Manifest Glaucoma Trial. *Ophthalmology* **123**: 1173–1180.
- O’Leary N, Crabb DP & Mansberger SL (2010): Glaucomatous progression in series of stereoscopic photographs and Heidelberg Retina Tomograph images. *Arch Ophthalmol* **128**: 560–568.
- Prata TS, Lima VC, de Moraes CG, Guedes LM, Magalhaes FP, Teixeira SH, Ritch R & Paranhos A Jr (2011): Factors associated with topographic changes of the optic nerve head induced by acute intraocular pressure reduction in glaucoma patients. *Eye (lond)* **25**: 201–207.
- Raza AS & Hood DC (2015): Evaluation of the structure-function relationship in glaucoma using a novel method for estimating the number of retinal ganglion cells in the human retina. *Invest Ophthalmol Vis Sci* **56**: 5548–5556.
- Schrems-Hoesl LM, Schrems WA, Laemmer R, Horn FK, Juenemann AG, Kruse FE & Mardin CY (2014): Confocal Laser Scanning Tomography to Predict Visual Field Conversion in Patients With Ocular Hypertension and Early Glaucoma. *J Glaucoma*. [Epub ahead of print].
- Strouthidis NG, Scott A, Peter NM & Garway-Heath DF (2006): Optic disc and visual field progression in ocular hypertensive subjects: detection rates, specificity, and agreement. *Invest Ophthalmol Vis Sci* **47**: 2904–2910.
- Tan JC & Hitchings RA (2004): Reversal of disc cupping after intraocular pressure reduction in topographic image series. *J Glaucoma* **13**: 351–355.
- The European Glaucoma Society. (2014): Terminology and guidelines for glaucoma, 4th edn. Savona, Italy: PubliComm.
- Varma R, Steinmann WC & Scott IU (1992): Expert agreement in evaluating the optic disc for glaucoma. *Ophthalmology* **99**: 215–221.
- Weinreb RN, Zangwill LM, Jain S et al. (2010): Predicting the onset of glaucoma: the confocal scanning laser ophthalmology ancillary study to the Ocular Hypertension Treatment Study. *Ophthalmology* **117**: 1674–1683.
- Williams RL (2000): A note on robust variance estimation for cluster-correlated data. *Biometrics* **56**: 645–646.

Received on March 5th, 2016.

Accepted on September 12th, 2016.

Correspondence:

HannaMaria Öhnell, MD

Inga-Marie Nilssons gata 38

SE-205 02 Malmö

Sweden

Tel: +46 (0)40 332781

Fax: +46 (0)40 337481

Email: hannamaria.ohnell@med.lu.se

This work was financially supported by grants from the Swedish Research Council K98-27X and the National Eye Institute, Bethesda, Maryland, USA (grants nos. U10-EY10260 and U10EY10261) and by the Järnhardt Foundation. Both Dr Bengtsson and Dr Heijl are consultants for Carl Zeiss Meditec. Dr Heijl reports receiving grants from Allergan and Santen, outside the submitted work.